Ben-Gurion University of Negev
Faculty of Natural Science
Department of Computer Science
Introduction to Computational and Biological Vision

AUTOMATIZATION OF COMPUTED TOMOGRAPHY PATHOLOGY DETECTION
Final Project

Semyon Medvedik, Elena Kozakevich
{medvedik,elenako}@cs.bgu.ac.il

1 March 2006

Contents

1 Computed Tomography: Definitions and Background

1.1 Definition of CT

Computed tomography (a.k.a. CT), originally known as computed axial tomography (CAT) and body section roentgenography, is a medical imaging method employing tomography where digital geometry processing is used to generate a three-dimensional image of the internals of an object from a large series of two-dimensional X-ray images taken around a single axis of rotation. The word ”tomography” is derived from the Greek tomos (slice) and graphia (describing). CT produces a series of axial images which can be manipulated, through a process known as windowing, in order to recreate the image in a different plane.

1.2 History and Background

The CT system was invented by Godfrey Newbold Hounsfield of EMI Central Research Laboratories in Hayes, England. Hounsfield conceived the idea in 1967, and it was publicly announced in 1972. The first commercial CT machine using X-rays was limited to making tomographic sections of the brain, but acquired the image data in about 4 minutes and the computation time was about 7 minutes per picture. The images were relatively low resolution, being composed of a matrix of only 80 x 80 pixels. Modern multi-detector, multi-row CT systems can complete a scan of the chest, for example, in less time than it takes for a single breath hold and display the computed images in near real time. Images that used to take hours to acquire and days to process are now accomplished in seconds. The number of cross sectional images that can be produced has increased from about a dozen to many hundreds.

1.3 How It Works?

Each X-ray slice data is generated using an X-ray source that rotates around the object; X-ray sensors are positioned on the opposite side of the circle from the X-ray source. All data scans are combined into 3D image by the mathematical procedure known as tomographic reconstruction.

1.4 Common Uses

Since it provides detailed, cross-sectional views of all types of tissue, CT is one of the best tools for examining the chest and abdomen. It is also the preferred method for diagnosing many different cancers. CT can clearly show even very small bones as well as surrounding tissues such as muscle and blood vessels. This makes it invaluable in diagnosing and treating spinal problems and injuries to the hands, feet and other skeletal structures. Another most known CT usage is diagnosis of cerebrovascular accidents and intracranial hemorrhage also know as “Head CT” or “CT Brain”. CT can also play a significant role in the detection, diagnosis and treatment of vascular diseases that can lead to stroke, kidney failure or even death.

2 Project Goals

Major project goals are to:

- Examine CT images analysis process.
- Examine various possibilities of automatization or semi-automatization of CT analysis process.
- Observe performance of several techniques applied to the problem.

3 CT images analysis process

The principle of computed tomography is that the image of a 3-dimensional object could be reconstructed from an infinite number of 2-dimensional projections of the object. Computer processing and analysis of medical images covers a broad number of potential topic areas, including image acquisition, image formation/reconstruction, image enhancement, image compression and storage, image analysis, and finally image-based 3-dimensional visualization. Then 3D image, accepted from "spiral" or "slice" scan is examined by a radiologist, who is a physician experienced in CT and other radiology examinations.

Let's review previous attemps to analyze computer produced images. In the early 70's, for example, as cardiac nuclear medicine images became available, simply viewing the change of the volume of blood in the heart between end-diastole and end-systole was an exciting use of this new modality. However, the facts that

- the data was acquired in digital form
- that it was feasible that a computer could semiautomatically outline a "region of interest" that contained the entire left ventricle

facilitated the measurement of a quanlitative index of ejection fraction, making this one of the earliest forms of "digital image analysis" that became clinically useful.

Still, untill recent technological breakthrough, the output of helical CT scan, for example, was simple series of images fo single study, each each of which contributes diagnostic information; however, it is very uncomfortable to work with hundreds of grayscale images. Thus User Friendly Graphic applications were developed in order to make easier the radiologist analysis of the scan results and allow him to browse through various sections of the pseudo-3-dimensional image. Nowadays applications produce full 3-dimensional presentaion of CT scan results, combined from previously mentioned 2-dimensional images. There is severe amount of software, that specializes in representation of CT scan results. Among them we can mention "CD diagnostic" developed in Petah-Tikva and is used in "Soroka" hospital; "EIKONA3D" manufactured by "ALPHA TEC Ltd.", which include much more options such as 3D geometric transformations, 3D edge detection and more.

Earlier, most widely available rendering techniques were "maximum intensity projection(MIP)" and "shaded surface display". However, these techniques use only a portion of the data set, may fail to show important relationships between structures, and are highly prone to errors introduced by improper choice of attenuation thresholds or by inaccurate tracing of anatomic borders. Luckly, powerful graphics workstations have become financially feasible for most radiology departments and allows true volume-rendering three-dimensional imaging, which is more accurate and more useful than MIP or shaded surface display. Viewing a volume-rendered three-dimensional image in real time is an impressive, fast, and interactive process that allows the radiologist to highlight or to strip away anatomic structures for optimal depiction and understanding of the pathologic morphology.

But still these tools are designed to visualize the CT scans and make the analyst's (radiologist's) life easier.

4 Automatization and Semi-automatization of CT Analysis Process.

The increased number and availability of medical imaging modalities has yielded a concomitant increase in the demand for automatic or semiautomatic image interpretation tools designed to manage the large amount of information made available by these imaging techniques. Segmenting anatomic structures on medical images and reconstructing their shape represents a particularly challenging problem due to the complexity and variability of human anatomy. Several classical image processing techniques (e.g., multiple thresholding, region growing, and morphologic filtering) have been applied to try to solve this problem, with variable outcomes.

Such techniques tend to be unreliable when segmenting a structure that is surrounded by other structures with similar image intensity (e.g., low-contrast structures). Moreover, these techniques typically make very limited use of the available knowledge of the underlying anatomy. User intervention is usually required to separate adjacent structures of similar image intensity.

CT image interpretation by human beings is often limited due to the non-systematic search patterns of themselves, the presence of structural noise in the image, and the presentation of complex disease states requiring the integration of vast amount of image data and clinical information. Recently, computer-aided diagnosis (CAD), defined as a diagnosis introduced by a radiologist who uses the output from a computerized analysis of medical images as a "second opinion" in detecting lesions, assessing extent of disease, and making diagnostic decisions, is being used to improve the interpretation components of medical imaging. There are many approaches for image segmentation, such as feature thresholding, contour based techniques, region based techniques, clustering, and template matching. Each of these approaches has its advantages and disadvantages in terms of applicability, suitability, performance, and computational cost.

There are multiple techniqes which may be applied to automatic analysis of CT images. We will observe some of them and their usage. First of all we need to make the following observation:
Computed Tomography is used as strong diagnostic tool in many various parts of human anatomy. Thus we must distingiush between Lungs, Abdonimal, Brain, Liver CT, etc. Each anatomy region mentioned above has different structure and it is obvious that image of each one of them will have different shape and texture. Thus different approaches must be taken in order to analyze each of these CT scan results.

Now we will examine several techniques applied to different parts of human anatomy.

4.1 Computerized Detection of Pulmonary Nodules on CT Scan

The following research describes attempts to analyze Lung CT scan and determine pathologies. The reseaches developed several steps algorithm. Initially, 2 level of segmentation were performed. First - to isolate thorax from the background. Second - to isolate lungs from the thorax. Then rolling ball algorithm was applied to the contours of the lungs. Two-dimensional ball was placed tangential to each contour (edge) point. Each time the ball thouched more then one contour point, was declared as pathology found. Moreover, various segmentation and classification techniques were applied in order to isolate inner nodules and declare them as pathology. This method was applied to the database consists of 17 lungs CT scan with approximately 180 nodules. The method discovered 82% of actual nodules. Despite of this findings it is necessary to mention that there were about 70% of "false alarms", i.e. the method discovered nodules that were a part of normal anathomy. Still, the number of "false" nodules might be reduced by adjusting gray level filter. We may summarize this by noticing that this method demonstrated relativily good performance in it's ability to detect pulmonary nodules on lungs CT scans.

4.2 Image Segmentation with Knowledg-Guided Robust Active Contours

A novel segmentation technique was developed that combines a knowledge-based segmentation system with a sophisticated active contour model. This approach exploits the guidance of a higher-level process to robustly perform the segmentation of various anatomic structures. The user need **not** provide initial contour placement, and the high-level process carries out the required parameter optimization automatically. Knowledge about the anatomic structures to be segmented is defined statistically in terms of probability density functions of parameters such as location, size, and image intensity (eg, computed tomographic attenuation value). The capability of combining image features with simple shape constraints, as well as robustness to image noise, make the use of active contours a very powerful technique for segmentation.

An active contour is essentially a set of points describing a curve in two dimensions (2D) whose characteristics are controlled by an energy functional. The energy-minimizing instance of this curve results in the final segmentation. The purpose of this functional is twofold. On one hand, the energy term should be smaller when the contour lies in proximity to features of interest on the image. For example, in the segmentation of an anatomic structure, the functional should be minimized when the active contour coincides with the edges of the structure. However, the boundaries of a structure are not always well defined. In particular, image noise or poor image contrast can result in inaccurate edge definition. This type of problem is overcome in the active contour model with the inclusion of additional terms in the energy functional. These terms are responsible for controlling, for example, the continuity and smoothness of the contour. The novelty of this study consists in the introduction of additional constraints into the energy functional that enforce consistency of the active contour with the a priori knowledge regarding the structure to be segmented. There are several properties we would like to be able to transfer from the apriori model to the contour. The set of energy functionals that enforce different types of constraints on contour evolution:

- *Center*. With an appropriate energy functional, the contour location, defined in terms of its centroid (cx, cy), can be forced to be close to the expected location (according to the knowledge base) of the structure to be segmented.
- *Size*. The optimal size of a contour that is expected to be approximately circular can be defined in terms of the equivalent radius. Aspect ratio (described later) is used in an energy term that weights deviation from this expected circularity.
- *Average Image Intensity*. The expected pixel values of a structure to be segmented can also be determined by introducing an applicable term into the energy functional. For example, the average pixel value inside the contour can be evaluated and compared with expectations defined in the knowledge base.
- *Aspect Ratio*. The aspect ratio (AR) of the model can be controlled by adding a term such that $AR = ly/lx$, where lx and ly are the lengths of the principal axes of the contour. This term takes into account the deviation from circularity, which shape is assumed when estimating contour size. The set of possible features that can be transferred to the model from the a priori information is not limited to those just described, and more sophisticated constraints on contour shape and texture can be enforced.

Performance of this method is as following: The performance of the knowledge-guided active contour method was tested on several CT data sets. In particular,the segmentation of lung nodules was investigated on chest CT scans and of the kidneys on abdominal CT scans. The fully automated system correctly identifies different anatomic regions of interest such as the chest walls, airspace, mediastinal region, and areas of increased attenuation within the airspace. The anatomic regions are segmented approximately, thereby serving as crude landmarks to guide the segmentation of

structures of interest. The significance of the method becomes more clear when one considers the results of an attempt to segment a nodule in contact with the mediastinum via a large vessel .The original knowledge-based system yields satisfactory results on only two of the four sections; it is incapable of segmenting the lesion without ”flooding” into the mediastinum. Morphologic operators cannot be applied automatically to reliably segment lesions that are in contact with the mediastinum because, unlike the smooth chest wall, the mediastinum has irregular boundaries. On the other hand, the active contour algorithm correctly identifies and segments the lesion on all four sections. To demonstrate the effectiveness of the framework in segmenting different types of anatomic structures, the system was also tested on some CT scans of the abdomen. The goal was to accurately segment the kidneys. This task is made particularly challenging by the small gradient in attenuation level between the kidney and the neighboring organs (liver and spleen). The results obtained with the knowledge-guided active contour method are comparable ,but somewhat less conservative in that more of the renal structure is correctly segmented.

4.3 Automatic liver segmentation for volume measurement in CT Images

Automatic liver segmentation and volume measurement based on the segmentation are the most essential parts in computer-aided diagnosis for liver CT. Liver segmentation, in general, has been performed by outlining the medical image manually or segmenting CT images semi-automatically. Due to the two following reasons, liver segmentation that plays an important role for CAD, is difficult:

1. The first one is the proximity of the liver and other organs or muscles with the similar intensity. It makes difficult to resolve by observation of intensity discontinuity alone since partial-volume effects cause the discontinuity to weaken where the structures touch.

2. The second one is the variation in both shape and scale across patients even on the same patient.

Since adjacent organs have similar intensity with the liver, a direct liver-extraction approach without preprocessing may also extract undesirable boundaries resulting from its adjacent organs as fault positive/negative errors. A new automatic liver segmentation algorithm in abdominal CT images, using the combination of region based and contour-based approaches, exploits both medical priori knowledge, for example, the general shape, location, and gray level of the liver, and deformable contour method using labeling based search algorithm. Finally, total liver volumes were calculated from segmented areas of the liver to evaluate the patients for entire or partial liver transplantation and CAS. There are three stages in the algorithm:

- Image simplification as preprocessing
- Detecting a search range detection with initial liver contour by using morphological filter
- Contour-based segmentation using labeling-based search algorithm that refines the initial liver boundary obtained in the second stage

Now lets examine each one of these steps:

1. **Image simplification.**For image simplification, the researchers considered a priori knowledge of the liver on abdominal CT image, such as shape, location, and intensity value. First of all, they declared the region of interest (ROI). Then, the right-bottom region was discarded, that is from a priori knowledge - the liver cannot be located in the right-bottom area but is generally located in the left side of CT images. Therefore, the regions in this area cannot be part of the liver but can be eliminated so as to reduce the search area and computational efforts for liver

boundary. Second, they investigated and analyzed the intensity distribution of several samples that are manually segmented liver and adjacent muscle. In addition, CT number correspond to the liver and muscle into the gray level was interpreted. Multilevel thresholding based on the analysis of a priori knowledge makes many other organs or tissues disappear in ROI blocks and identify the liver and adjacent region as clear or blur liver region.

2. **Search range detection.** To detect the precise liver boundary search range detection is presented. For the search range, the researchers found the first and second search region by performing multiscale morphological operations on the threshold image of the image simplification.

   (a) *First multiscale morphological filtering.* Image simplification classifies each pixel into clustered liver class and scattered non-liver class. Accordingly, the researchers performed mathematical morphology filtering to reduce scattered class and detect liver object. This set theoretic, shape oriented approach treats the image as a set and the kernel of operation as another set, commonly known as structuring element (SE). Different standard morphological operations, namely (erosion, opening, closing, etc.) are basically set theoretic operations between these two sets. The shape and the size of the SE play important roles in detecting or extracting features of given shape and size from image. The performance of multiscale morphological filtering in the threshold image reduces the circumferential object of the liver, preserves the shape of the liver, and detects the initial liver region.

   (b) *Region-labeling.* Because of the pixels of the other organs or muscles which have the similar intensity values with the liver, the multiscale morphological filtering can make the dispersed noises, hence reducing the noise and detecting the coarse liver region was needed. Therefore researchers performed on the 4-connected region-labeling algorithm. The technique for region finding that is used in the region-labeling algorithm is breadth-first search approach. After performing of the region-labeling algorithm, the largest labeled region is marked out for the candidate region of the liver.

   (c) *Partition clustering.* The result of region-labeling is the coarse liver region. This is due to the fact that adjoining non-liver organs and muscles are still remained. In order to detect the finer liver region, the researchers classified the labeled image into three classes based on the result of morphological filtering. The adjoining tissues or muscles in the liver have mainly higher or lower intensity value than that of the liver. This processing divides the region into the adjacent noise of the liver and the liver region. After the class of the adjacent noise was reduced, the researchers got the fine initial liver region. Finally, the image of the first search region was constructed by performing the different order's composition between erosion and dilation operation of the mathematical morphological opening on the clustered initial liver region.

   (d) *Second morphological filtering.* In the clustering, instead of reducing the adjacent noise, any liver region can be reduced. To solve this problem, reverse filtering of the first morphological filtering was performed on the region of the original image corresponding to the previous labeled region. This processing recovers some regions of the liver that are damaged or reduced in the previous morphological filtering. The second search region is constructed. Final search range is determined by excluding the second search region from the first search region. Since most of the liver boundaries are located in this search range, precise automatic liver segmentation is possible by using the deformable contour algorithm within this range. Furthermore, the initial liver boundary which will be a guidepost for search algorithm is constructed by extension of the second search region to original liver size.

3. **Contour-based liver segmentation.** The initial liver boundary acquired by multiscale morphological filtering is coarse liver contour. Therefore, researchers presented the labeling-based search algorithm that deforms the initial liver boundary within the search range to find clear and final liver contour. For the search algorithm, researchers made gradient-label map.

   (a) *Gradient-label map.* If we observe an area within an isolable-contour map that extends from one object's center to its boundary within the search range, we can see a distinct pattern. Where the intensity gradient is monotonic in raw image, the pattern of labels in the isolable-contour map is monotonic as well. We can observe dense contour patterns in the areas of abrupt intensity gradients and widespread contour patterns in the areas of gradual intensity gradients . To make gradient-label map, the researchers enhanced the isolable-contour map by using gradient magnitude into the weighing factor. The positive morphological gradients usually indicate borders between neighbor regions.

   (b) *Labeling-based search algorithm.* The description of the entire pattern of liver contours as a relationship of the intensity distribution, allows us to manipulate pixels easily that are related to contours. We can classify the entire pattern into the three cases. In the first case, the liver is adjacent to the air region which has low intensity value. The second is the case that liver is touched to the ribs or the kidney which has high intensity value. In the last case in which the liver is adjoined to the stomach or the lung, the intensity value within the liver boundary is distributed through the low gray level. For the optimal path from each pixel, researchers formulate the local cost function at each candidate pixel. We can get a correct liver contour by finding optimal path which is the minimal cost value. The gradient direction or orientation adds smooth constraint to the boundary by associating a relatively high cost for sharp changes in boundary direction .For volume measurement of the liver, we calculate the volume by using thickness and interval information of the slice and size of the pixel.

The results of the proposed algorithm were evaluated by comparing with the results of manual tracing as a gold standard by experts. The comparable measure used is exclusive-or method. This method can detect the fault positive and negative error. The average correctness of the segmentation is about 96%. It shows the proposed algorithm is effective automatic segmentation scheme of the liver in CT images. Even though the proposed algorithm involves so many preprocessing steps, computational complexity is not bad. The processing time of image simplification and search range detection takes about 20-60 s/slice and contour-based segmentation takes some more time because it is similar to dynamic programming being less than $O(n)$ for a contour having n points which are allowed to move to next point . Total processing time is normally about 1-3 min/slice on Pentium 4 3.0 GHz system.

4.4 Object Recognition in Brain CT-Scans using Knowledge-Based Segmentation Algortihms

Brain is the most complicated part of human anatomy. Thus, automatic recognition techniques observed above are not sufficient to perform valid recognition of pathology and must be replaced or, at least significantly improved. It is obvious that support from automated brain CT interpretation systems is useful in cases where the images are observed routinely or where diagnosis could benefit from a quantitative approach to avoid the inter- or intra-observer variability. Despite the large variety of methods which have been proposed in the literature, automated segmentation of complex medical images remains at the stage of laboratory research. Their quality depends strongly on the efficiency of the low and intermediate level vision algorithms which are applied to extract information from the image data. There are systems based on region oriented segmentation and knowledge-based

labeling, and edge-based segmentation and labeling. **Template matching** is a filtering method for detecting particular objects in an image. An approach based on deformable templates residing in a digital brain atlas, permits mapping between the image data and the brain atlas by constrained minimization of predefined similarity measures. This kind of approach produces good results for small and local shape changes but fails for large and global misalignments or deformations.

The second approach is **region oriented segmentation combined with knowledge-based labeling** obtained by pixel classification based on the homogeneity of some features of the objects. There are systems that adopt a knowledge-based approach and some of them integrate an uncertainty reasoning mechanism to label the image segments. Others use high level features extracted from segmented images to match image regions with brain structures residing in the brain model which is described as static domain knowledge.

Edge oriented segmentation is sometimes applied. Tools are supplied for extracting contours, for optimizing region boundaries, and for propagating contours to neighboring slices. Original concepts are introduced in many of the previously mentioned systems, but none of them really combines all these concepts in one integrated system. In the new approach, the researchers emphasized the methodology which is used in their system to integrate various conceptually different techniques in order to overcome the classical bottlenecks of automated medical image interpretation, which are discussed below. Medical images represent biological structures having an almost infinite set of shapes, which cannot easily be described in terms of shifted and rotated patterns, which can occur in a large variety of different orientations, scales, and which are therefore difficult to extract from the image data. The complexity of brain CT-scans is also due to partial volume effects, which disturb the edges and produce contrast degradation by spatial averaging, and to the typical problems such as patient movement, beam hardening, and reconstruction artifacts. Although it is known that there is a strong relation between gray value and brain tissue type, different brain objects can be characterized by very similar gray values. These image characteristics are responsible for the over- and undersegmented results observed when unsupervised segmentation is applied. Since one brain structure can be perceived in multiple image representations, the problems of segmentation (i.e., the definition of regions based on constant local image features) and labeling (i.e., the classification of the regions into object classes) cannot be dissociated: We are facing a mixed detection, recognition, and estimation problem which means that-in order to improve the reliability - domain knowledge should be used to direct the interpretation process from the low level vision stages on.

Numerous image processing techniques for extracting various types of image primitives exist (2-D regions, edges, simple shapes, and texture), each of them having its own strength and weaknesses when applied individually. To overcome this difficulty, we adopt two strategies:

- Selection of the optimal algorithm given the nature of the problem which has to be solved, by making use of a knowledge representation of the expertise and heuristics used by the image processing experts.
- Integration of the information from multiple techniques so that each image property can be determined by fusing the results from various techniques.

There are segmentation approaches which integrate edge and region information. Evaluation by human observers reveals that these segmentation methods perform well on simple images (e.g., tool images), but due to the absence of context sensitive control, their performance decreases when they are applied on complex images (e.g., aerial photographic images). In the new system, multiple image primitives are extracted from the images by different image processing algorithms. The regions and edges are treated as complementary data to improve the quality of high-level image interpretation and the points are used as context information to register the images. Multiple types of object descriptions are introduced in the model as well, such as regions, lines, and points of interest. The scoring data fusion technique has been used in the system for aggregating information from

different image primitives. The new system combines the image primitive information produced by different low level vision techniques in order to improve the reliability of the segmentation and the image interpretation. It is implemented in a blackboard environment that is holding various types of prior information and which controls the interpretation process. The scoring model is applied for the fusion of information derived from three types of image primitives (points, edges, and regions). A model, containing both analogical and propositional knowledge on the brain objects, is used to direct the interpretation process. The linguistic variables, introduced to describe the propositional features of the brain model, are defined by fuzzy membership functions. Constraint functions are applied to evaluate the plausibility of the mapping between image primitives and brain model data objects. Procedural knowledge has been integrated into different knowledge sources. Experimental results illustrate the reliability and robustness of the system against small variations in slice orientation and interpatient variability in the images.

5 Experiments and Results

The general assumption of our experiments was that general structure of healthy human anatomy is common. The main idea was compare "sick" CT scan image with generalized "healthy" CT scan image combined from finite amount of CT scan of "healthy" organs (e.g. Brain CT), and show results on the input image by marking the "pathology" regions. The algorithm had two basic step:

1. **Creation of Sample Database.** The idea was to perform an averging of finite amount of an images. Two techniqes were applied:
   - Mathematical average of pixel's value. This technique provided very bad results, since it blured edges and caused information loss.
   - Median of pixel's value. Better results were received. The edges remained visible, information loss decreased. Still this technique was not enough to create meaningfull database due to erroneous assuption. As we mentioned above, the assupmtion was the healthy human organs have very similar structure. As we discovered, this assumption was not true. By taking two diffirent Brain CT scans we found that despite the fact the both of them were scans of healthy brain, they differed significantly since $a)$ human anatomy is never the same; $b)$ there is almost impossible that two images were made exactly from the same angle. This observation derive from the fact that there is always two different systems (machines) that were used to perform the scan. Thus, there always will be differences even between two scan fo same organ if it is performed on different machines. Since we have tried to average scans of different organs, the average was unacceptable and this was the first reason to the failure of the idea.
2. **Examine the Input Image According to Previously Contructed Database.** We took various approaches to isolate pathology areas in the CT scans.
   - Edge Detection. The idea was to run an edge detection algorithm both database image and input image. After this both edge maps were supposed to be compared by simple difference. The remaining part of edges was supposed to identify possible pathology regions. The results were disappointing. Since the input image was the Brain CT scan, and it's structure was very complex, the result produced by "good" edge detection algorithm, such as Canny, were too strict, and thus to much information remained after we differed the images. This means that the result edge map contained edges not only of pathology region, but also all mismatches of the image's contours. The less "accurate" edge detectors, such as Prewitt simple did not acquire requested imformation, i.e. were unable to find edges of pathology.

Figure 1: Input Brain Scan. Metastasis in the right part of brain.

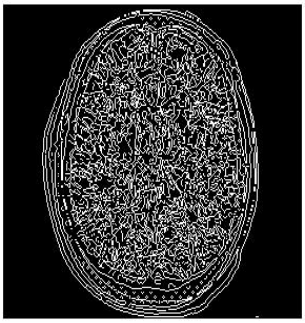

Figure 2: No results can be found.

- Distance Transform Algorithm. The second idea was to use distance map. The algorithm was as following: First we perform edge detection of database image; afterwards we run the distance transform algorithm on the result image and receive map that represents distance of each pixel from the closest edge. The idea was as following: If we compare this processed database image to input image, that was also processed by edge detector, and apply appropriate distance threshold, we will be able to identify pathology without taking care of noise produced by mismatching edges. In fact this idea was refinement previous attempt. This idea didn't provided any results, since the complexity of brain structure, there were too many edges and thus, no pixel exceeded given threshold. We've simple got black square.
- Segmentation. The greatest advantage of this technique was that with appropriate usage we do not need no previously processed database. The segmentation was performed using "Relaxation Labeling" algorithm as it was presented in the lectures. We received a positive results, but not enough to declare that computer discovered the pathology by itself. The results are shown below.

  As we can see from the images above, the simple segmentation performed via Relaxation Labeling algorithm identifies pathologies, but it also shows the bones. The computer itself can't distinguish between pathologies with the help of segmentation only.

Figure 3: Input Brain Scan. Metastasis in the right part of brain.

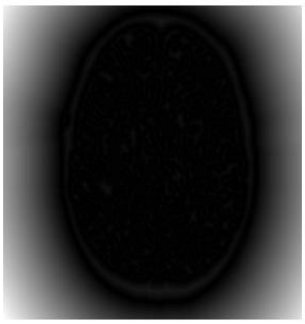

Figure 4: No results can be found.

6 Discussion and Conclusions

In this paper we have reviewed several CT analysis automatization techniques. There are a variety of methods which have been proposed in the past. We also tried to examine several ideas of ourselves. We have deduced that there are many open issues and number of difficult problems in this area of research, though many encouraging results were observed. From our attempts to solve this problem we cam make one important conclusion. We examined three naive different approaches. The only one that showed conceivable results was naive implentation of segmentation via relaxation labeling algorithm. Thus we understand that segmentation approach is essential for this issue.

We have to make several important observations from the previous assays in this art of field: segmentation methods were used at the precomputation stage in each one of the approaches. By combining this observation with our results, we conclude that the segmentation is a very basic tool for computer-aided diagnosis(CAD),in particular, CT.

We have surveyed the studies that handled CT scans of the following organs:brain,liver,lungs and abdominal. Dispite the fact that every one of them used the segmentation method as the basic tool at the early stage, rather distinctive directions were taken afterwards. And that is for the following reasons:

- Each of the organs mentioned above has absolutely different structure, hence in the CT scan

Figure 5: Input Brain Scan. Calcification of soft brain tissues. Fracture in coronal bone

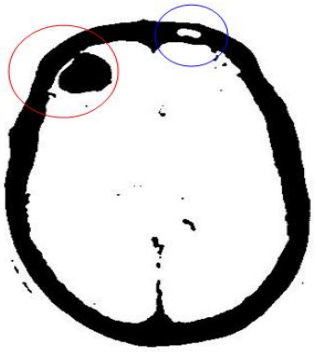

Figure 6: Segmentation Results.

image it has different shape, intensity and texture.

- The adjacent organs may have similar attributes as the examined one, therefore the analysis may become very difficult even by radiologist.

Finally ,we can conclude,based on the reasons described above, that medical image analysis continues to be an active area of research.It has many difficult challenges ahead, both in terms of addressing the practical need of cummunity(e.g. physicians and radiologists), as well as the theoretical side of CAD.

7 References

1. Riccardo Boscolo, Matthew S. Brown, Michael F. McNitt-Gray. Medical Image Segmentation with Knowledge-guided Robust Active Contours. RadioGraphics 2002; 22:437-448

2. William R. Hendee .Cross Sectional Medical Imaging: A History. RadioGraphics 1989; Volume 9, Number 6, Monograph

3.]. Samuel G. Armato, Maryellen L. Giger, Catherine J.Moran, James T. Blackburn, Kunio, Heber MacMabon. Computerized Detection Of Pulmonary Nodules on CT Scans. RadioGraphics 1999; 19: 1303 - 1311

4. Michael P. Federle .Current Status and Future Trends in Abdominal CT. RadioGraphics 1998; 18:1555-1568

5. Hongyi Li, Rudi Deklerck, Bernard De Cuyper, A. Hermanus, Edgard Nyssen, and Jan Cornelis. Object Recognition in Brain CT-Scans: Knowledge-Based Fusion of Data from Multiple Feature Extractors. IEEE Transactions On Medical Imaging, vol. 14, no. 2, June 1995

6. James S. Duncan and Nicholas Ayache. Medical Image Analysis: Progress over Two Decades and the Challenges Ahead .IEEE Transactions On Pattern Analysis And Machine Intelligence. Vol. 22, No. 1, January 2000

7.]. Seong-Jae Lim, Yong-Yeon Jeong, Yo-Sung Ho. Automatic liver segmentation for volume measurement in CT Images. Journal of Visual Communication and Image Representation, 2005